

Establishing a Tattoo Center and Pro Bono Tattoo Removal Service in New York City



MARIE LEGER MD PHD

**METRO DERMATOLOGY
ELMHURST QUEENS
MARCH 27, 2018**

Bispebjerg Tattoo Clinic, Copenhagen



Nation's First Tattoo Clinic Finds Ink Answers In NYC

The William Street Tattoo Center in the Financial District is a first-in-the-nation clinic dedicated to tattoo-related medical issues.

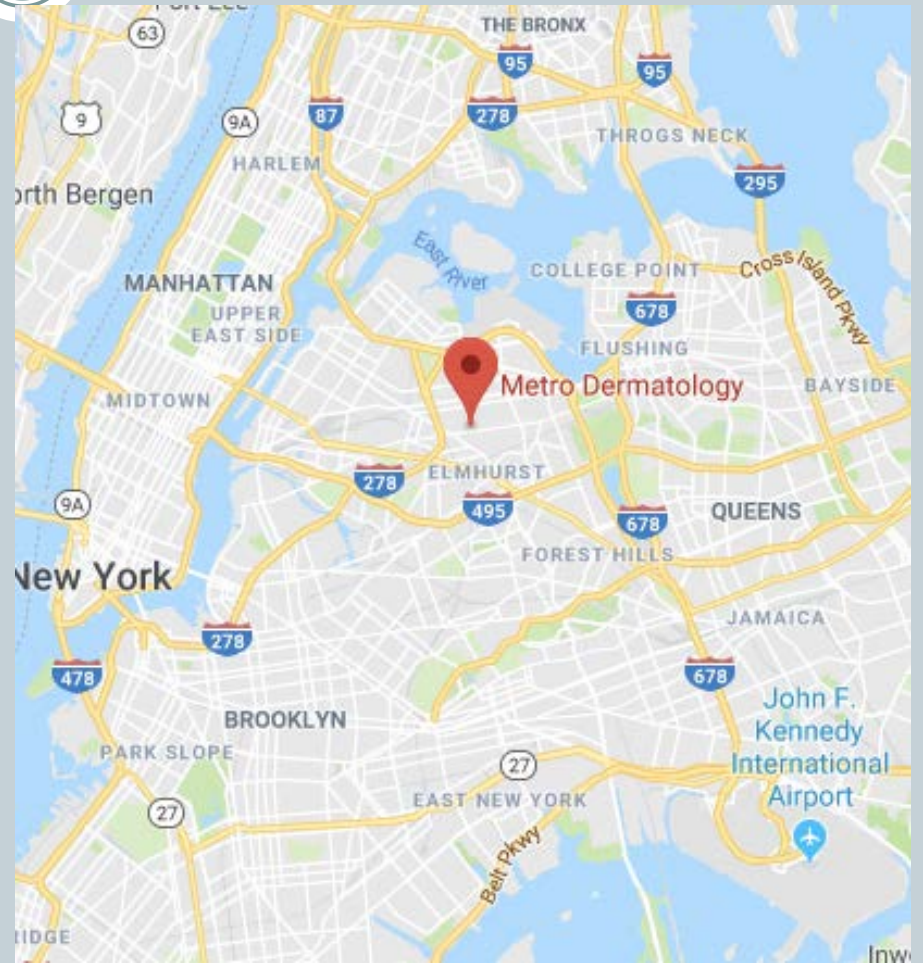By [Noah Manskar](#), Patch Staff | Apr 15, 2018 9:00 am ET | Updated Apr 16, 2018 11:37 am ET

[Like 198](#) [Share](#) 



Metro Dermatology Tattoo Center in NYC

- Established at Cornell University in 2017
- Moved to Metro Dermatology in New York City in 2018
- Referrals
 - Tattoo artists
 - Primary care
 - Dermatologists



Metro Dermatology Tattoo Center



- **Education of public and tattoo artists on adverse reactions and skin health**
- **Education of tattoo artists on skin cancer screening**
- **Lectures on tattoo reactions to US dermatologists**
 - American Academy of Dermatology 2019
 - Boston University Grand Rounds 2019
 - University of Pennsylvania Grand Rounds 2018
 - New York Metropolitan Hospital 2018
 - New York Dermatological Society 2018
- **Pro-bono tattoo removal**

Case 1



- 35 year old man with tattoo obtained on right forearm
- Had warts on his hand at the time of tattoo application

Case 1: Warts Associated with Tattoo


- Over the course of the next several weeks and months developed verrucous papules within tattoo
- Treated with combination of topical imiquimod and liquid nitrogen

Case 2

47 yo F with raised itchy portion of tattoo for one year. Tattoo had been obtained 22 years prior, but the red portion was touched up one month before the tattoo became raised and pruritic

PMH: DM

Case 2: Tattoo Allergy



Biopsy: Acanthotic epidermis with pseudoepitheliomatous hyperplasia. Perivascular lymphoplasmacytic dermal infiltrate with a few eosinophils and red tattoo ink

Tattoo Allergy

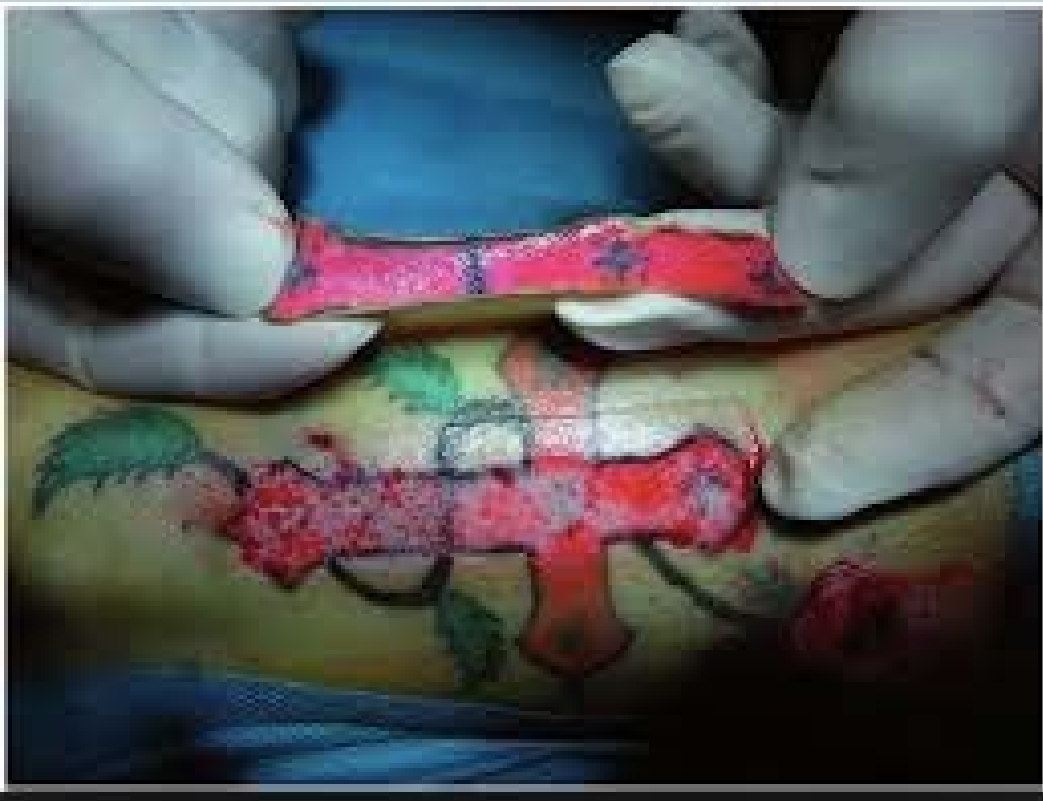

- **Red ink on back and chest also raised. Patient unaware**

ORIGINAL ARTICLE

Introduction of dermatome shaving as first line treatment of chronic tattoo reactions

Mitra Sepehri¹, Bo Jørgensen¹, and Jørgen Serup²



Dermatome Shaving



Dermatome Shaving



Plastic Surgery Removal of Tattoo



Case 3

25 yo M with pruritic bumps associated with black and red tattoo ink on left arm, right arm, left calf, and right thigh started 3 months prior, most recent lesion 2 weeks prior. Affected tattoos obtained from 1.5-5 years ago

PMH: none

ROS: negative

Case 3: Tattoos and Sarcoidosis



**Biopsy: Sarcoidal
granulomas in association
with exogenous black
carbon pigment**

**Workup: mild
transaminitis, Subtle hilar
LAD normal PFTs**

ACS unveils free tattoo removal program for trafficking victims, ex-gang members

Medical professionals with tattoo removal experience have signed on to perform the service for free.



- Children come from foster care, runaway children, undocumented immigrants
- Recruited on internet
- Nearly 3,000 New York City youths were identified as either trafficked or at risk of trafficking in a 2017 report by the NYC Safe Harbour Program — a 21 increase from 2016

Legal Aid Society Exploitation Intervention Project



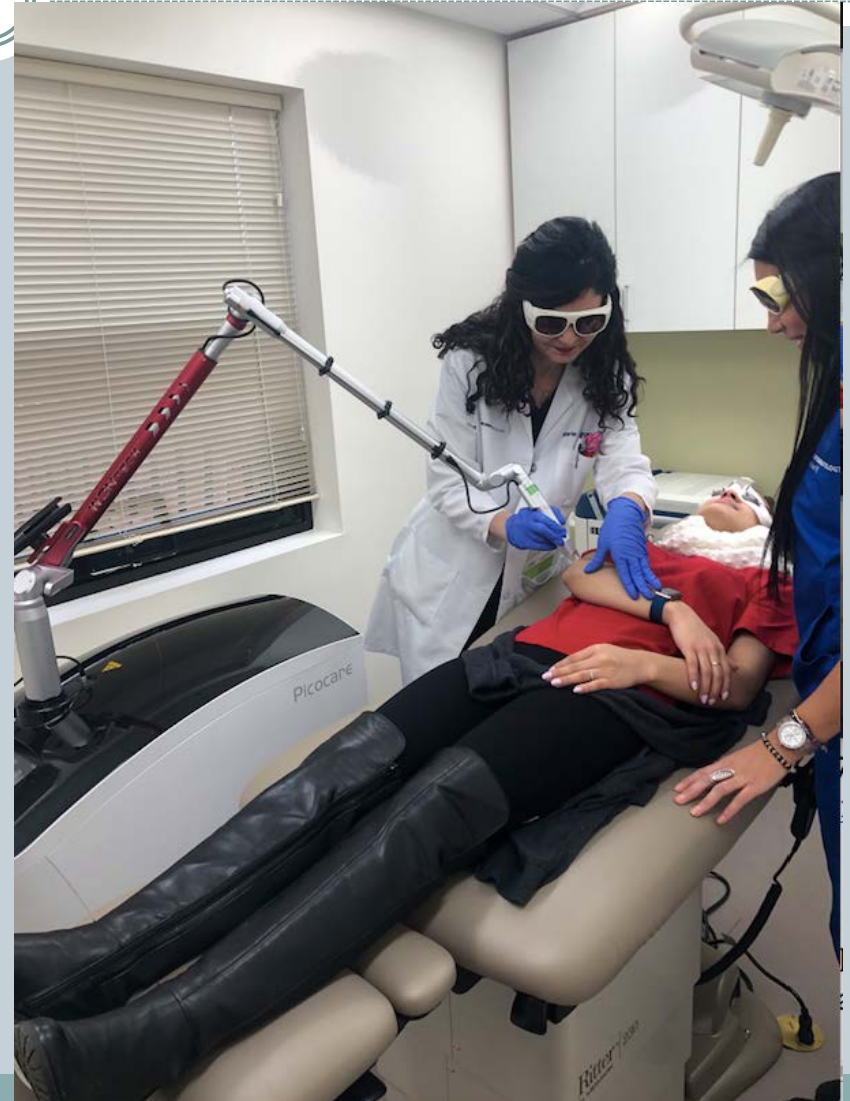Metro Dermatology Pro-bono Tattoo Removal

- Pro-bono tattoo removal for victims of sex trafficking
- Established October 2018
- Referral Sources
 - Administration for Children's Services New York
 - Legal Aid, Brooklyn
- Every third Saturday of the month
- Spanish, Mandarin, Korean, Hindi spoken



Tattoo Removal Program

- 12 patients treated as of March 2019
- Same day as patients being seen in general dermatology clinic
- Topical anesthesia combined with injected anesthesia
- Pico laser technology used
- Child care available



Pro-bono Tattoo Removal

Trafficked for 7 years and forced to have intercourse with 25 men a day

Free from her trafficker for 10 years but still has forced tattoos of his initials

She insists on always keeping them covered

Tattoo removal is a critical element in her healing process

Thank you!



- macleger@gmail.com